

Multisymptom Oral Presentation in Type II Diabetes Mellitus: A Case of Candidiasis, Xerostomia, and Burning Mouth Syndrome

Arina Shafia

Universitas Islam Sultan Agung, Indonesia
Email: drg.arinashf@unissula.ac.id

KEYWORDS

Oral Candidiasis, Type II Diabetes Mellitus, Burning Mouth Syndrome, Xerostomia.

ABSTRACT

Oral candidiasis is a fungal infection of the tongue and oral mucosa caused by *Candida* species, often occurring in immunocompromised states such as type II diabetes mellitus. In diabetic patients, fungal infections may be accompanied by Burning Mouth Syndrome (BMS) and xerostomia. A 53-year-old male presented with a three-day burning sensation localized to the left side of the tongue, alongside reduced taste sensation limited to salty and spicy flavors and persistent dry mouth. The patient had a six-year history of type II diabetes mellitus but had discontinued antidiabetic medication three months prior. Treatment included chlorinated dioxide mouthwash (three times daily), xylitol (three times daily), nystatin oral suspension (four times daily), a one-time dose of fluconazole 150 mg, and Becomzet (once daily). The patient was advised to adhere strictly to medications, maintain oral hygiene, and attend follow-ups. Symptom improvement was noted after consistent therapy use. Managing oral candidiasis in poorly controlled type II diabetes mellitus, especially when accompanied by Burning Mouth Syndrome and xerostomia, demands a comprehensive strategy. Successful treatment relies on precise drug selection and patient adherence to therapy and oral care. This case underscores addressing systemic conditions alongside local treatment to resolve symptoms and prevent recurrence.

INTRODUCTION

Oral candidiasis is a fungal infection affecting the tongue and other parts of the oral mucosa, characterized by excessive fungal growth and superficial tissue invasion (Abbas, Abdullah, Mohammed, & Al-Mahmood, 2025; Tamai & Kiyoura, 2025). It is an opportunistic infection predominantly caused by *Candida* species, commonly involving the oral mucosa (Faccioni et al., 2025; Tkaczyk et al., 2025). Several risk factors are associated with the development of oral candidiasis, including immunosuppression (due to HIV, chemotherapy, medications, or systemic diseases such as diabetes mellitus), hyposalivation (resulting from local/systemic diseases or chemotherapy/radiotherapy), and disturbances in oral microbiota, often caused by antibiotic therapy.

Diabetes mellitus is a common endocrine disorder that impairs the host immune response to infection (Berbudi, Khairani, & Tjahjadi, 2025; Kotsiri, Xanthi, Domazinaki, & Magiorkinis, 2025). One of the most frequent opportunistic infections in individuals with diabetes mellitus is candidiasis, particularly oral candidiasis. Diabetes mellitus (DM) is a chronic metabolic disorder resulting from pancreatic beta-cell dysfunction, leading to prolonged elevated plasma glucose levels (Parsi, Saharkhiz, Farani, Bakhtiyari, & Alipourfard, 2025; Yen et al., 2025). It is a multifactorial disease often accompanied by systemic

complications, such as hypertension, kidney disease, retinopathy, recurrent skin fungal infections, and oral diseases including gingivitis, periodontitis, and biofilm-associated lesions (Bertolini et al., 2022; Ray, 2023). Patients with type II diabetes mellitus are at increased risk for opportunistic *Candida* infections—both oral and vaginal—as well as periodontal disease, gingivitis, dental caries, and salivary dysfunction (Grisi et al., 2022; Rodrigues, Rodrigues, & Henriques, 2019).

As of 2017, the global prevalence of adult-onset diabetes (ages 20–79) reached 425 million, and by 2045, the World Health Organization and International Diabetes Federation estimate this number will rise to approximately 629 million (Nanditha, Chamukuttan, Raghavan, & Ramachandran, 2020; Ye, Yao, Huang, & Chen, 2025). According to the 2012 Indonesian Ministry of Health's Disease Control and Environmental Health Profile, the prevalence of oral candidiasis in Indonesia remains high, with reported cases reaching 7,098 and 24,482.7 The incidence of oral candidiasis with predominant *C. albicans* isolation has been reported at 45% in neonates, 45–65% in children, 30–45% in healthy adults, 50–65% in long-term denture wearers, 65–88% among residents in acute and long-term care facilities, 90% in patients undergoing chemotherapy for acute leukemia, and 95% in individuals with HIV infection.

Aside from oral candidiasis, burning mouth syndrome (BMS) and xerostomia are also common oral conditions found in individuals with diabetes mellitus (Keser & Pekiner, 2025; Ye et al., 2025). Diabetes mellitus (DM) is considered a systemic factor contributing to the development of secondary BMS. The burning sensation in the oral cavity observed in diabetic patients is often associated with inadequate glycemic control, metabolic disturbances in the oral mucosa, as well as vascular and nerve dysfunction. The prevalence of BMS in the general population varies from 0.7% to 15%, depending on the diagnostic criteria applied, with a higher frequency observed in older adults and predominantly among postmenopausal women (Bechman et al., 2025; Martins Almeida, Oliveira, Santos, Lara, & Cardoso, 2025).

Xerostomia, defined as a subjective sensation of dry mouth, is characterized by a reduced salivary secretion rate (Park, 2025; Zhao, Ran, Huo, Gan, & Li, 2025). Several contributing factors have been identified in diabetic patients, such as aging and the use of certain medications. In both type 1 and type 2 diabetes, salivary gland function may be impaired due to parenchymal damage, altered microcirculation, systemic dehydration, and persistently high blood glucose levels. 10 Reports indicate that around 16% of individuals with type 1 diabetes mellitus experience xerostomia, whereas the condition is observed in approximately 54% of those with type 2 diabetes mellitus worldwide. A study conducted at Haji Hospital, Surabaya in 2006 recorded a xerostomia prevalence of 76% among type 2 diabetic patients. Meanwhile, another study at Dr. Saiful Anwar Hospital, Malang in 2011 showed a prevalence of 15.6% in the same population.

The diagnosis of oral candidiasis is primarily clinical, and may be confirmed through microscopic evaluation using lesion swabs stained with potassium hydroxide (KOH) or Periodic Acid-Schiff (PAS), as well as culture on Sabouraud Dextrose Agar (SDA) (Cao et al., 2025; Nusynowitz et al., 2025). In certain cases, biopsy may be required for definitive diagnosis.

Multisymptom Oral Presentation in Type II Diabetes Mellitus: A Case of Candidiasis, Xerostomia, and Burning Mouth Syndrome

Given the complex interrelationship between type II diabetes mellitus and oral health manifestations, this case report aims to comprehensively document the clinical presentation, diagnostic approach, and management strategy of a patient presenting with concurrent oral candidiasis, burning mouth syndrome, and xerostomia. Through detailed clinical documentation and analysis, this study seeks to provide clinicians with practical insights into recognizing and managing these overlapping oral conditions in diabetic patients. The findings from this case will contribute to improved clinical decision-making, enhance understanding of multifactorial oral manifestations in diabetes, and ultimately support the development of more effective integrated treatment protocols that address both systemic and local factors in diabetic oral care.

RESEARCH METHOD

Case Report

First Visit

A 53-year-old male presented with a chief complaint of a burning sensation on the left side of the tongue, which had been persistent for the past three days and had not received any prior treatment. The patient reported occasional disturbances in taste perception, being able to detect only salty and spicy flavors. He also complained of oral dryness. The medical history revealed a diagnosis of type 2 diabetes mellitus for the past six years. However, the patient had not been taking his diabetes medication consistently for the last three months, though he claimed to still be taking metformin regularly. He had just resumed receiving antidiabetic medication from the local primary health center one day prior to presentation. There was no family history of similar symptoms, and the patient denied any known drug or food allergies. He also reported that he had lost his job three months earlier, which led to the discontinuation of his national health insurance (BPJS) and subsequent interruption of diabetes treatment. The patient is an active smoker.

Upon examination, the patient appeared in good general condition. His body weight was 70 kg, height 160 cm, and blood pressure were measured at 116/60 mmHg. Extraoral examination revealed no signs of lymphadenopathy. Intraoral examination showed an Oral Hygiene Index (OHI) score of 2.24, indicating good hygiene. Oral dryness was observed, evidenced by the adherence of the dental mirror to the mucosa. The dorsum of the tongue appeared atrophic, with a single, well-demarcated reddish lesion (Figure 1), accompanied by a burning and painful sensation. Additionally, two whitish plaques with darkened edges and diffuse borders, each approximately 2 mm in diameter, were observed on the right and left buccal mucosa (Figures 2 and 3).

Sialometric assessment revealed an unstimulated salivary flow rate of 0.04 ml/min and a stimulated flow rate of 1.7 ml/min, both indicative of hyposalivation. Based on the subjective complaints and objective findings, the initial working diagnosis was suspected oral candidiasis.

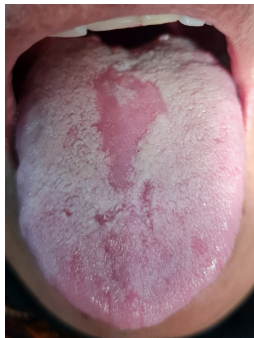

Figure 1. Erythematous atrophic lesion on the dorsal tongue

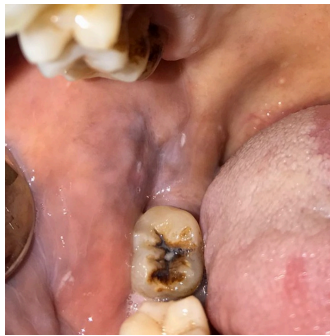

Figure 2. White plaque on the right buccal mucosa

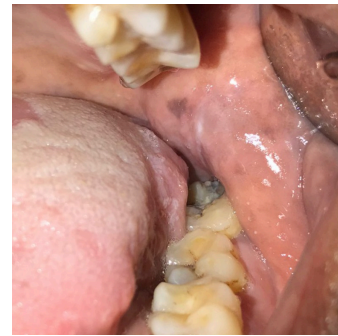


Figure 3. Diffuse black plaque on the left buccal mucosa

Source: Author's clinical documentation, 2024

The patient was prescribed chlorine dioxide mouthwash, to be used three times daily, and xylitol, recommended for oral consumption three times per day. Comprehensive oral health education was provided, emphasizing the importance of consistent medication use, maintaining optimal oral hygiene, and attending a follow-up visit the following week. In addition, the patient was instructed to undergo further laboratory testing, including a Gram-stained tongue swab and Toluidine blue staining, to support diagnostic confirmation.

Second Visit

At the first follow-up appointment, the patient reported that the burning sensation on the tongue persisted. He also continued to experience oral dryness. Additionally, the patient complained of a new pain localized to the right cheek. Despite these ongoing symptoms, the patient confirmed that he had been using all prescribed medications regularly.

Intraoral examination revealed persistent signs of oral dryness, evidenced by adherence of the dental mirror to the mucosa. The dorsum of the tongue still exhibited a single well-defined reddish atrophic area (Figure 4), accompanied by a burning and stinging sensation. On the right buccal mucosa, multiple well-defined white plaques with darkened borders were noted, each approximately 2 mm in diameter (Figure 5). On the left buccal mucosa, a single, diffuse-bordered black plaque measuring approximately 2 cm in diameter was observed (Figure 6).

Sialometric testing showed improvement in salivary flow compared to the initial visit, with an unstimulated salivary flow rate of 0.16 ml/min and a stimulated flow rate of 2.0 ml/min, though both remained below normal reference values.

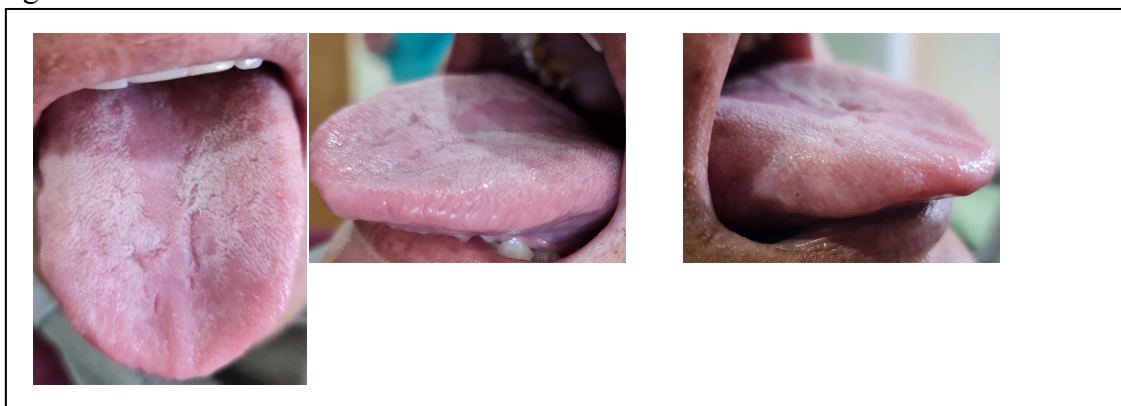


Figure 4. Persistent atrophic lesion on the dorsal tongue (second visit)

Source: Author's clinical documentation, 2024

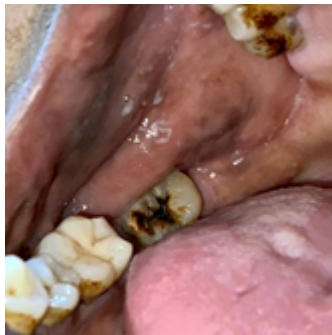

Figure 5. Multiple well-defined white plaques on the right buccal mucosa

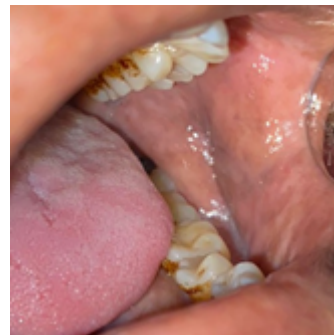

Figure 6. Single black plaque on the left buccal mucosa

Source: Author's clinical documentation, 2024

The Gram-stained tongue swab did not reveal the presence of *Candida* species. However, antifungal therapy was continued due to the strong clinical presentation suggestive of oral candidiasis. Toluidine blue staining was performed to evaluate suspicious plaque-like lesions observed on both the right and left buccal mucosa. These lesions, characterized by white areas with darkened margins, mimicked features commonly associated with potentially malignant disorders. The Toluidine blue test revealed diffuse staining, indicating that the lesions were non-malignant in nature (Figure 7).

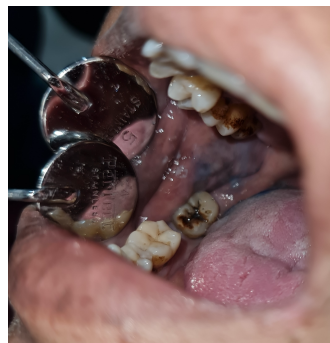

Figure 7. Toluidine Blue staining result of the buccal mucosa lesion

Source: Author's clinical documentation, 2024

The patient was prescribed 0.2% Chlorhexidine Gluconate mouthwash, to be used three times daily; Nystatin Oral Suspension, four times daily; and Xylitol, to be taken orally three times a day. The patient was thoroughly educated on the importance of adhering to the medication regimen, maintaining good oral hygiene, and attending a follow-up appointment the following week.

Third Visit

At the second follow-up visit, the patient reported that the burning sensation on the tongue had persisted but had significantly improved. The previously reported pain in the right cheek had resolved. However, the patient continued to experience a dry mouth. The patient confirmed adherence to the prescribed medications.

Intraoral examination revealed signs of xerostomia, indicated by the adherence of the mouth mirror to the mucosal surface. Multiple atrophic areas were observed on the dorsal tongue, appearing similar in color to the surrounding tissue with diffuse borders (Figure 8), accompanied by a persistent burning and stinging sensation. Additionally, a single plaque-like lesion was present on the right and left buccal mucosa, measuring approximately 2 mm in diameter, dark in color, and with well-defined margins (Figure 9).

Sialometry results showed an unstimulated salivary flow rate of 0.2 ml/min and a stimulated flow rate of 2.16 ml/min, indicating a mild improvement in salivary gland function.

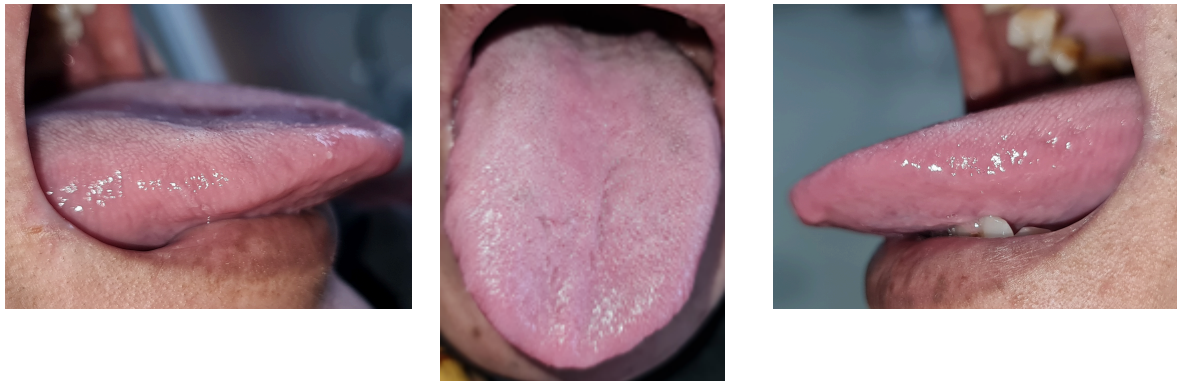


Figure 8. Multiple atrophic areas on the dorsal tongue (third visit).

Source: Author's clinical documentation, 2024

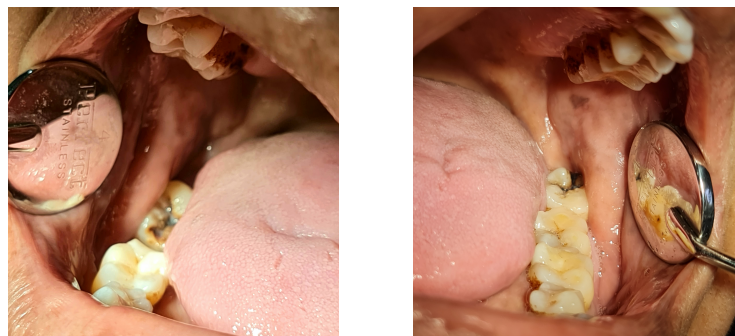


Figure 9. Persistent plaque-like lesions on the buccal mucosa

Source: Author's clinical documentation, 2024

The patient was prescribed Fluconazole 150 mg tablets and Becomzet, both to be taken once daily. Additionally, Chlorhexidine Gluconate 0.2% mouthwash was prescribed to be used three times daily, along with Xylitol, to be consumed three times daily. The patient was advised to adhere strictly to the medication regimen, maintain optimal oral hygiene, and return for a follow-up visit the following week.

Fourth Visit

At the third follow-up visit, the patient reported that the burning sensation on the tongue had resolved, although mild discomfort occasionally occurred when consuming spicy food. The patient also stated that the sensation of oral dryness had subsided. Furthermore, the patient confirmed adherence to the prescribed medications.

Multisymptom Oral Presentation in Type II Diabetes Mellitus: A Case of Candidiasis, Xerostomia, and Burning Mouth Syndrome

Intraoral examination revealed a moist oral cavity, as indicated by the absence of mirror adhesion to the mucosa. Healing was observed in the previously atrophic lesion on the dorsum of the tongue (Figure 10), and the patient no longer experienced burning or pain in the area.

Sialometry results showed an unstimulated salivary flow rate of 0.44 mL/min and a stimulated salivary flow rate of 2.68 mL/min.

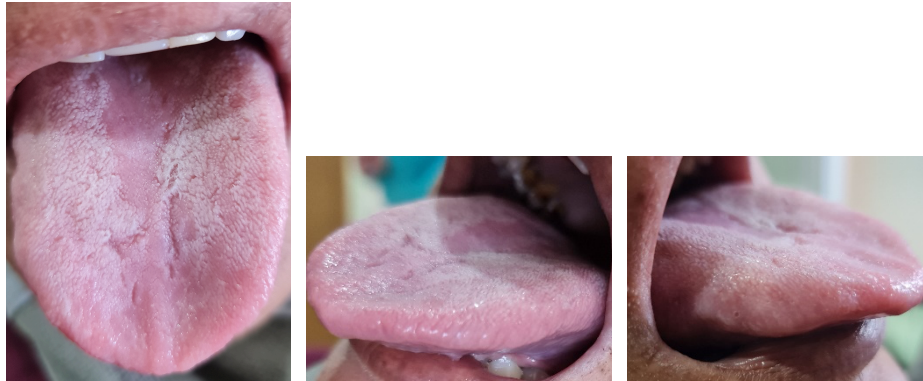


Figure 10. Healing of the atrophic lesion on the dorsal tongue (fourth visit)

Source: Author's clinical documentation, 2024

Although treatment was declared complete, the patient was advised to continue the prescribed medication regimen. The patient was prescribed Becomzet, to be taken once daily, Chlorhexidine Gluconate 0.2%, to be used three times daily, and Xylitol, to be consumed three times daily.

The patient was educated on the importance of adhering to the medication schedule, maintaining proper oral hygiene, avoiding spicy foods, routinely monitoring diabetes mellitus at the public health center (puskesmas), and reducing smoking habits.

RESULT AND DISCUSSION

Oral candidiasis is a common fungal infection of the oral cavity, primarily caused by species from the *Candida* genus, especially *Candida albicans*.¹² However, other species such as *Candida glabrata*, *Candida tropicalis*, and *Candida krusei* may also be involved. Interestingly, non-*albicans* *Candida* species have been shown to infect individuals over the age of 80 more frequently than younger populations. *Candida albicans* is part of the normal flora found on mucosal surfaces, the gastrointestinal tract, and the female genital tract. Under certain conditions, such as immune suppression or physiological disturbances—particularly in individuals with diabetes mellitus—*C. albicans* can become pathogenic.

Infection development typically begins with the organism's adherence to host tissues. This host–pathogen interaction is mediated by specific components of the fungal cell wall, including adhesins and corresponding host cell receptors. Once adherence occurs, *C. albicans* can invade the mucosal epithelium. Key enzymes involved in this invasion process include mannopeptidase and acid phosphatase, with extracellular hydrolytic enzymes like proteases and phospholipases playing crucial roles in degrading host tissue. The host immune status largely determines the subsequent response to this penetration.

Initial adhesion of *Candida* cells is facilitated by non-specific mechanisms such as hydrophobic interactions and electrostatic forces. This is followed by more specific attachment through fungal surface adhesins that recognize host ligands like proteins, fibrinogen, and fibronectin. These adhesins specifically bind to amino acids and sugar residues on the host cell surfaces¹⁵. The pathogenicity of *Candida* is driven by a combination of factors including adhesion, evasion of host immune defenses, and the ability to invade and damage tissues. The hyphal form of *C. albicans* penetrates the epithelial surface perpendicularly, reaching the stratum spinosum. These penetrating hyphae are enriched with enzymes such as proteinases and lipases. Unlike other *Candida* species, *C. glabrata* does not form true hyphae and lacks the ability to independently invade epithelial layers. It also secretes very low levels of key enzymes like secreted aspartyl proteinases (SAPs) and phospholipases (PLs). However, in mixed infections, *C. albicans* facilitates the invasion of *C. glabrata* into the oral epithelium. Once *C. albicans* has breached the epithelial barrier, the final stage of infection—tissue damage—occurs, typically marked by loss of the superficial epithelial layer. *C. albicans* can induce both apoptosis and necrosis in oral epithelial cells. In a study using reconstituted human oral epithelium, *C. albicans* hyphae caused marked disorganization of the epithelial structure, whereas *C. glabrata* resulted in considerably less tissue damage.

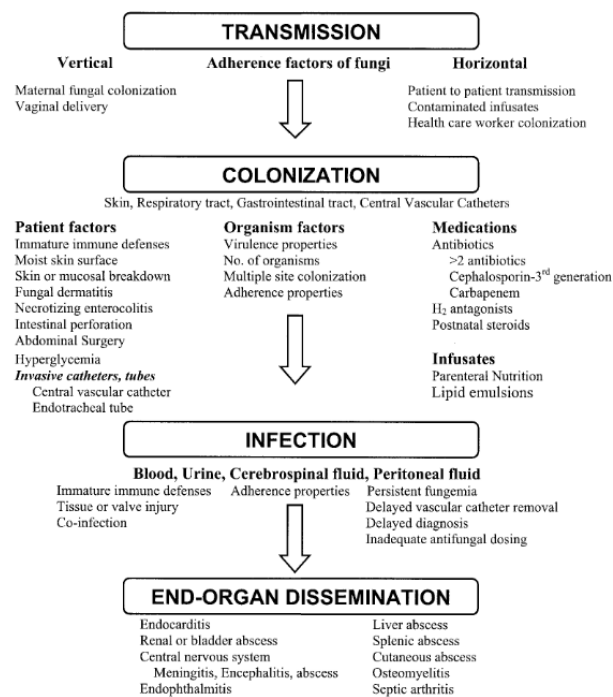


Figure 11. Pathogenesis of Fungal Colonization and Infection

The transition of *Candida albicans* from a harmless commensal organism to a pathogenic state is highly dependent on various predisposing factors. The continued rise in the incidence of candidiasis reflects several contributing elements, including the widespread use of broad-spectrum antibiotics, immunosuppressive agents, and medical devices such as catheters. Additionally, the increasing number of solid organ and hematopoietic stem cell transplants has significantly contributed to the growing prevalence of this fungal infection.

Table 1. Predisposing Factors for Oral Candidiasis.

Multisymptom Oral Presentation in Type II Diabetes Mellitus: A Case of Candidiasis, Xerostomia, and Burning Mouth Syndrome

Local Factors
1. Salivary dysfunction, including both quantitative and qualitative reductions, as well as diminished antimicrobial properties of saliva.
2. Poor denture hygiene and prolonged denture wear.
3. Ill-fitting dentures, which may cause mucosal trauma.
4. Topical corticosteroid therapy, such as steroid mouth rinses, topical gels used to manage oral mucosal diseases, or inhaled corticosteroids.
5. Tobacco smoking.

Systemic Factors
1. Age-related immunosenescence, affecting both infants and the elderly.
2. Broad-spectrum antibiotics, which alter the local oral microbiota.
3. Immunosuppressive therapy, including systemic corticosteroids, biologic immunomodulators, and other immunosuppressive drugs.
4. Chemoradiation therapy, especially for head and neck cancers.
5. Immunocompromised conditions, such as thymic aplasia, hyper-IgE syndrome (Job syndrome), chronic mucocutaneous candidiasis, Sjögren's syndrome, graft-versus-host disease, HIV/AIDS, and leukemia.
6. Nutritional deficiencies, particularly of iron, zinc, magnesium, selenium, folic acid, and vitamins A, B6, B12, and C.
7. Endocrine disorders, including diabetes mellitus, Addison's disease, and hypothyroidism.

Patients commonly present with complaints of white patches on the tongue and/or buccal mucosa. There is often an associated history of immunosuppressive conditions such as smoking, recent use of antibiotics and/or corticosteroids, immunosuppressive therapy in transplant patients, denture use, malnutrition, or other underlying conditions. Clinically, oral candidiasis typically appears as white pseudomembranous plaques that affect the oral mucosa, tongue, and both the hard and soft palate. These plaques are usually not painful but may be associated with taste disturbances and angular cheilitis (cracking or soreness at the corners of the mouth). The lesions are often difficult to remove with a tongue spatula, and if scraped off, may leave behind erythematous, painful, and sometimes bleeding areas. Some patients may also present with Candida-related rashes or infections in other parts of the body.

There are several clinical presentations and classification systems for oral candidiasis (OC). However, the most straightforward classification categorizes oral manifestations into four major types: acute pseudomembranous candidiasis, acute atrophic candidiasis, chronic hyperplastic candidiasis, and chronic atrophic candidiasis. It is important to note that more than one clinical form can present simultaneously in different areas of the oral cavity. Additionally, although non-albicans *Candida* species can cause oral candidiasis, the oral manifestations are clinically indistinguishable regardless of the *Candida* species involved.

In the present case, intraoral examination revealed dryness of the oral mucosa, indicated by the adherence of the dental mirror to the tissue, along with a clearly demarcated erythematous atrophic lesion on the dorsum of the tongue accompanied by burning and stinging sensations. Multiple white plaque-like lesions with dark margins (2 mm in diameter) were observed on the right buccal mucosa, and a single diffuse black plaque (2 cm in diameter) was seen on the left buccal mucosa. Based on these clinical features, the presentation is most consistent with acute atrophic candidiasis.

Diabetes mellitus (DM) is an endocrine disorder characterized by inadequate insulin production, leading to disruptions in nutrient assimilation, metabolic processes, and glucose homeostasis. Individuals with diabetes are at increased risk for several oral conditions, including oral infections, burning mouth syndrome, and xerostomia. Among diabetic patients, approximately 30% develop oral candidiasis due to biofilm-related infections or mucosal fungal colonization. Commonly prescribed systemic medications for DM—such as antihypertensives and diuretics—can reduce salivary flow, creating a favorable environment for biofilm accumulation. In such conditions, particularly when compounded by poor oral hygiene, the biofilm matures and contributes to the development of various oral diseases. In type 1 diabetes, the colonization rate of *Candida* spp. is higher (approximately 84%) compared to type 2 diabetes (68%), while only around 27% of non-diabetic individuals show similar colonization.

Fungal infections are frequently observed in diabetic patients, particularly when glycemic control is poor. *Candida* species are more prevalent in such cases, and increased salivary glucose levels have been linked to higher rates of oral *Candida* carriage. Numerous studies have demonstrated a significant correlation between *Candida* infections and diabetes mellitus. Two critical features associated with *Candida* pathogenicity in oral candidiasis are increased enzymatic activity and enhanced biofilm-forming ability. Studies have consistently shown a relationship between elevated hydrolytic enzyme activity and the pathogenic potential of *Candida* spp. isolates from diabetic individuals. Elevated blood glucose levels are associated with increased production of hemolysins, esterases, and phospholipases, enzymes that can degrade host cell membranes, initiate cell lysis, and promote fungal invasion. This enzymatic activity may also enhance inflammation by increasing vascular permeability, thereby impairing host immune defenses. Consequently, the heightened enzymatic activity observed in *Candida* spp. from diabetic patients may aggravate the clinical symptoms of oral candidiasis.

C. albicans induces both apoptosis and necrosis in oral epithelial cells. In studies using reconstituted human oral epithelium, the hyphal forms of *C. albicans* were shown to penetrate the tissue and cause significant epithelial disorganization. This contributes to atrophy of the tongue papillae. The burning and numbness often reported by patients may result from the loss of protective filiform papillae on the dorsal tongue surface, exposing free nerve endings in the atrophic mucosa. Additionally, taste disturbances may occur due to the loss of taste buds on the fungiform papillae along the tongue's dorsum and lateral edges, reduced salivary flow, and decreased salivary gustin levels.

Burning Mouth Syndrome (BMS), or oral dysesthesia, is characterized by a persistent burning sensation affecting the oral mucosa. While its exact cause remains unclear, associations with oral fungal infections have been clinically proposed as a potential contributing factor. This chronic pain can significantly impact both physical and psychological functioning and is often linked to sleep disturbances, anxiety, and depression.

Clinically, BMS presents with variable symptoms between individuals. The onset of pain can be gradual or sudden, often without a clear trigger. However, some cases may be associated with initiating factors such as dental procedures, trauma, the introduction of new medications, systemic illness, or major life stressors. Patients commonly describe a persistent burning, tingling, or sometimes itchy or numb sensation that lasts for four to six months. Most report

Multisymptom Oral Presentation in Type II Diabetes Mellitus: A Case of Candidiasis, Xerostomia, and Burning Mouth Syndrome

that the pain ranges from mild to moderate in intensity, and tends to either be present upon waking or intensify throughout the day.

Lamey and Lewis classified BMS into three types based on daily pain variation. Type 1 patients are typically symptom-free in the morning, with symptoms worsening as the day progresses, often associated with nutritional deficiencies or endocrine disorders such as diabetes mellitus. Type 2 presents with constant symptoms throughout the day and is commonly linked to chronic anxiety. Type 3 features intermittent symptoms with pain-free periods and may be related to allergic reactions to food or other substances.

Oral dysesthesia in patients with diabetes is thought to stem from poor glycemic control, metabolic changes in the oral mucosa, angiopathy, fungal infections, and diabetic neuropathy²¹. Although the exact mechanisms linking diabetes to neuropathy are not fully understood, prolonged hyperglycemia is believed to increase advanced glycation end-products (AGEs) and protein kinase C (PKC), contributing to peripheral nerve damage. AGE-induced oxidative stress can lead to microvascular injury, impairing blood supply to peripheral nerves. Additionally, elevated pro-inflammatory cytokines such as IL-6 and TNF- α in hyperglycemic states may also contribute to neuronal damage²⁴. In these patients, neuropathic pain can present as burning, tingling, stabbing, or electric shock-like sensations, which can be severely debilitating.

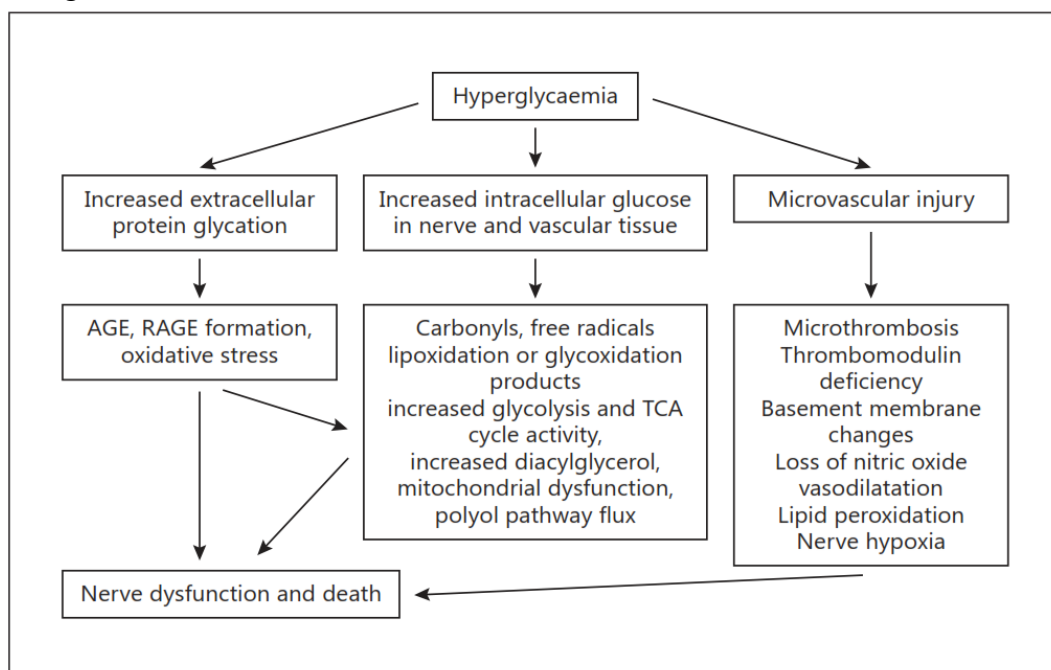


Figure 12. Pathogenesis Neuropati Diabetik²⁵

The reported prevalence of Burning Mouth Syndrome (BMS) in the general population varies between 0.7% and 15%, depending on the diagnostic criteria employed. BMS is most frequently observed in postmenopausal women, although younger women and men can also be affected. Most studies report a female-to-male ratio ranging from 5:1 to 7:1, and prevalence tends to increase with age in both sexes. Women are disproportionately affected, with some reports indicating a female-to-male ratio of approximately 3:1, and the majority of cases occur

in individuals over 50 years of age, particularly during the postmenopausal period. Based on various population samples and inclusion criteria, the estimated prevalence ranges from 0.7% to 4.5%. Oral *Candida* carriage was identified in 63.3% (50 out of 79) of patients with oral dysesthesia. However, the frequency and burden of oral *Candida* were not significantly elevated in these patients compared to those with other conditions. Nonetheless, individuals presenting with clinical signs of fungal infection or xerostomia showed an increased susceptibility to *Candida* infection.

In certain instances, infections may precede the onset of BMS symptoms. Specific pathogens frequently identified in patients with active BMS include *Candida*, *Enterobacter*, *Fusospirochetes*, *Helicobacter pylori*, and *Klebsiella*. Systemic conditions such as diabetes mellitus and peripheral neuropathy may also contribute to BMS symptoms, typically through mechanisms involving neuropathy. Xerostomia associated with BMS is believed to be more closely linked to neural dysfunction rather than salivary gland disorders. Mechanical factors such as bruxism, clenching, and tongue thrusting may serve as triggers, while psychological conditions often exacerbate the clinical manifestations.

Xerostomia is a subjective complaint characterized by a dry mouth sensation and is frequently associated with decreased salivary flow or hyposalivation. Saliva plays a critical role in maintaining oral health, and its reduction can lead to various complications, such as an increased risk of dental caries, greater susceptibility to oral infections, poor oral hygiene, and fissured tongue. Although xerostomia is often attributed to salivary gland dysfunction, definitive diagnosis requires further evaluation, including sialometry. Hyposalivation is typically defined by an unstimulated salivary flow rate below 0.1 mL/min or a stimulated flow rate below 0.7 mL/min (10). In patients with diabetes mellitus (DM), the average salivary flow rate ranges from 0.15–0.27 mL/min in males and 0.13–0.22 mL/min in females. Xerostomia is reported in 53% of individuals with type 1 diabetes (DMT1) and in 14–62% of those with type 2 diabetes (DMT2).

Salivary secretion is regulated by both branches of the autonomic nervous system: sympathetic stimulation influences protein composition, whereas parasympathetic stimulation increases salivary volume. Several factors are known to reduce salivary output in diabetic patients, including aging and disease duration. As many patients with DM are older adults, age-related degeneration of the salivary glands further contributes to reduced salivary flow. Poor glycemic control—specifically fasting blood glucose levels ≥ 100 mg/dL and postprandial levels ≥ 140 mg/dL—is associated with a higher risk of xerostomia.

In patients with diabetes mellitus (DM), xerostomia can be triggered by persistent hyperglycemia and polyuria, both of which contribute to systemic dehydration. This state of dehydration compromises the function of salivary glands, leading to reduced saliva production. Diabetic individuals are also at risk of developing complications such as neuropathy and angiopathy, which can impair the autonomic nervous system—both sympathetic and parasympathetic branches—that regulate salivary gland activity. The decline in neural function is largely attributed to elevated intracellular glucose levels within microvascular target cells, including capillary endothelial cells. This metabolic disturbance leads to increased mitochondrial production of reactive oxygen species (ROS), which in turn activates four major downstream pathogenic pathways: the polyol pathway, the advanced glycation end-products

Multisymptom Oral Presentation in Type II Diabetes Mellitus: A Case of Candidiasis, Xerostomia, and Burning Mouth Syndrome

(AGEs) and their receptors (RAGE), the protein kinase C (PKC) pathway, and the hexosamine pathway. These mechanisms mainly exert harmful effects by amplifying pro-inflammatory responses, which contribute to the development of angiopathy and neuropathy. Alterations in autonomic nerve function subsequently affect salivary gland performance, thereby increasing the risk of xerostomia in diabetic patients. In addition to physiological changes caused by diabetes, reduced salivary flow may also stem from medication-related side effects. Excess accumulation of certain drug compounds in salivary glands can lead to tissue toxicity and functional impairment. In patients with DM, xerostomia has been associated with medications like metformin, which is commonly prescribed to regulate blood glucose levels.

Metformin, a biguanide-class antidiabetic drug, works by suppressing hepatic gluconeogenesis and enhancing insulin sensitivity. It can accumulate in various organs and tissues, including the salivary glands. Metformin enters salivary gland acinar cells via passive diffusion mediated by Organic Cation Transporter 3 (OCT3), an electrogenic transporter located on both the basolateral and apical membranes of these cells. From the bloodstream, metformin diffuses into the acinar cells through OCT3, where it can exert cytotoxic effects on epithelial cells. Prolonged use of metformin may induce inflammation and necrosis within the salivary glands, ultimately reducing salivary secretion and contributing to xerostomia. Moreover, since metformin can also be excreted into the saliva, patients on long-term metformin therapy frequently report altered taste sensations, such as bitterness or a metallic taste in the mouth.

A differential diagnosis for this case includes Median Rhomboid Glossitis (MRG). MRG, also referred to as central papillary atrophy, is a benign, asymptomatic condition of the tongue characterized by the loss of filiform papillae in a rhomboid-shaped area on the dorsal midline of the tongue. Initially believed to be a developmental defect arising during embryogenesis due to incomplete tubercular fusion, current understanding suggests that MRG is more likely a chronic infection caused by *Candida albicans*. Clinically, MRG typically presents as a well-demarcated, symmetrical area of depapillation located anterior to the circumvallate papillae on the mid-dorsal surface of the tongue. The lesion may appear smooth or lobulated. In some cases, it may become indurated, fissured, or display darker pigmentation. The lesion often appears as a flat, bald, dark pink patch on the median tongue with peripheral white coating. While most individuals remain asymptomatic, some report persistent burning, irritation, or itching. In instances where the lesion contacts the opposing palatal mucosa, an associated inflammatory reaction—termed a “kissing lesion”—may develop.

The diagnosis of oral candidiasis is often clinical, based on characteristic presentation and predisposing risk factors. An erythematous, inflamed, and friable base observed after removal of the white plaque is indicative of oral thrush. Further confirmation may be achieved through culture of the lesion. Alternatively, Gram staining of the plaque revealing large, oval, Gram-positive yeasts can support the diagnosis. A KOH preparation of a lesion swab may also reveal pseudohyphae. The primary culture medium used for *Candida* isolation is Sabouraud Dextrose Agar (SDA). In cases of chronic hyperplastic candidiasis, a biopsy of the lesion may be necessary to detect fungal invasion. This is typically achieved using histological stains such as Periodic Acid-Schiff (PAS) or Gomori Methenamine Silver (GMS) stain. These stains

vividly highlight fungal elements such as blastospores and hyphae or pseudohyphae, which enable pathologists to identify the organisms as *Candida* species and, along with histopathological findings, confirm a diagnosis of chronic hyperplastic candidiasis.

In this case, a supportive diagnostic test via tongue swab and Gram staining revealed the presence of Gram-positive cocci and a few Gram-negative bacilli (+1), but no fungal elements were observed. This negative fungal finding may have resulted from inadequate or improper sampling technique. Nevertheless, based on the clinical intraoral examination, the presentation strongly pointed toward oral candidiasis. Therefore, antifungal therapy was initiated to relieve the patient's symptoms.

In many clinical situations, early malignant lesions in the oral cavity can be challenging to detect due to their nonspecific appearance, often leading to diagnosis only at an advanced stage. Toluidine Blue Vital Staining (TBVS) has been proposed as a useful adjunctive screening tool to help clinicians identify potentially malignant oral lesions. Toluidine blue is a cationic metachromatic dye that selectively binds to free anionic groups such as sulfates, phosphates, and carboxyl radicals present in macromolecules. Clinically, suspicious lesions that stain dark blue upon application of TB indicate dysplastic or malignant tissue, which is rich in deoxyribonucleic acid (DNA). In vivo, TB preferentially stains nuclei of immature, proliferative cells, which have higher DNA content than normal tissue, making them more absorbent to the dye. A meta-analysis has reported that TBVS can aid in diagnosing oral cancer in high-risk populations with a sensitivity of 93.5% and specificity of 73.3%.

In this case report, a Toluidine Blue Vital Staining (TBVS) examination was performed due to the presence of lesions resembling leukoplakia. Intraoral examination revealed white plaque-like lesions on the right and left buccal mucosa with poorly defined blackish margins, each approximately 2 mm in diameter. The TBVS test showed diffuse staining, suggesting that the lesion is unlikely to be malignant.

The salivary flow rate provides essential diagnostic information, and therefore, salivary gland function should be assessed using this technique, known as sialometry. Salivary flow rate is measured by collecting whole saliva—either from the oral cavity or directly from the major salivary glands. Various methods for collecting whole saliva exist, including draining, suction, spitting, and absorbent (sponge) techniques. The spitting method is the most commonly used. In this method, the patient is instructed to collect saliva in the mouth and spit it into a tube every 60 seconds over a period of 5 to 15 minutes. This can be done under stimulated or unstimulated conditions. Unstimulated salivary flow predominantly reflects basal gland activity and plays a critical role in maintaining oral cavity moisture and protection. A reduction in unstimulated whole saliva by 40–50% is typically associated with subjective complaints of dry mouth. Therefore, unstimulated whole saliva testing is particularly useful for evaluating the functional capacity of the salivary glands. To ensure accurate unstimulated saliva collection, patients are instructed to refrain from eating, drinking, smoking, chewing gum, and performing oral hygiene activities for at least 90 minutes before the test. They are also advised to minimize physical activity and talking prior to examination.

In this patient, sialometry of unstimulated saliva was performed. The patient was instructed to avoid eating, drinking, and chewing gum for 90 minutes prior to the test. The measurement was carried out over 5 minutes, resulting in a flow rate of 0.04 mL/min at the

Multisymptom Oral Presentation in Type II Diabetes Mellitus: A Case of Candidiasis, Xerostomia, and Burning Mouth Syndrome

first visit. This value, being below the diagnostic threshold of 0.1 mL/min, is indicative of salivary gland hypofunction. The patient primarily experienced hyposalivation during periods of inactivity.

The treatment regimen for this case included Chlorhexidine Gluconate 0.2% mouthwash, used three times daily; Nystatin oral suspension, taken four times daily; and Xylitol, consumed three times daily. The patient was educated on proper medication adherence, maintaining oral hygiene, and was scheduled for a follow-up the following week. At the third visit, the treatment plan was modified to include Fluconazole 150 mg tablets and Becomzet (a vitamin B complex) taken once daily, along with continued use of Chlorhexidine Gluconate 0.2% (3×/day) and Xylitol (3×/day). At the fourth follow-up, Becomzet, Chlorhexidine, and Xylitol were maintained with the same frequency.

The management of oral candidiasis is guided by four core principles: (1) early and accurate diagnosis of the infection; (2) identification and correction of predisposing factors or underlying conditions; (3) evaluation of the specific *Candida* infection type; and (4) appropriate antifungal therapy, while carefully weighing efficacy against toxicity. The choice of treatment depends on the *Candida* species involved, clinical presentation, and whether topical therapy is sufficient or if systemic treatment is warranted, particularly in cases of severe or recurrent infections. While topical antifungal agents are often effective in simple infections, chronic mucocutaneous candidiasis in immunocompromised patients may require systemic therapy.⁸ There are several classes of antifungal agents, including the polyene group (e.g., amphotericin B, nystatin, natamycin), azole derivatives (e.g., ketoconazole, econazole, clotrimazole, miconazole, fluconazole, itraconazole), as well as other groups such as allylamines (e.g., terbinafine), griseofulvin, and flucytosine.

Nystatin, a polyene antifungal agent, is frequently used in the treatment of oral candidiasis. It is derived from *Streptomyces noursei* and is hygroscopic with a distinctive odor. Nystatin is poorly soluble in chloroform and ether and readily degrades in aqueous or plasma solutions. It exhibits antifungal activity against yeasts and molds but is inactive against bacteria, protozoa, and viruses. Nystatin acts as both a fungistatic and fungicidal agent and selectively binds to ergosterol in fungal cell membranes. The resulting polyene-ergosterol complex forms membrane pores, disrupting cell permeability and leading to the loss of intracellular components. At sufficient concentrations, this causes potassium leakage and fungal cell death.

One of the triazole-class antifungal agents, fluconazole, continues to be the first-line treatment for both localized and systemic candidiasis. Its mechanism of action involves the inhibition of the enzyme lanosterol 14 α -demethylase, which plays a key role in the conversion of lanosterol to ergosterol, a vital component of the fungal cell membrane. This inhibition leads to the accumulation of a toxic intermediate, 14 α -methyl-3,6-diol, resulting in reduced ergosterol content in the fungal cell membrane. Consequently, the structure and function of the membrane are disrupted, ultimately inhibiting fungal growth.

Chlorine dioxide is a topical non-steroidal anti-inflammatory agent with broad-spectrum antimicrobial properties, making it effective in preventing further inflammation. It functions by releasing oxygen, which contributes to the healing of damaged tissues. Oxygen is crucial

for cellular metabolism, particularly in the production of adenosine triphosphate (ATP). Additionally, oxygen promotes angiogenesis, enhances keratinocyte differentiation, migration, and re-epithelialization, and stimulates fibroblast proliferation and collagen synthesis, all of which are essential in tissue repair. Moreover, oxygen supports the production of superoxide radicals, which are utilized by polymorphonuclear neutrophilic leukocytes (PMNs) to eliminate pathogens such as bacteria. As a result, chlorine dioxide contributes significantly to the prevention of bacterial, viral, and fungal infections, particularly in ulcerated lesions.

Xylitol is a tooth-friendly sweetener commonly used in chewing gum as a substitute for sucrose. It possesses a sweetness similar to that of sucrose but with approximately 40% fewer calories. Chewing xylitol-containing gum stimulates salivary reflexes through both mechanical (mastication) and chemical (taste) stimulation. The act of chewing enhances salivary flow via pressure receptors in the oral cavity, while taste perception sends sensory signals that increase salivary gland activity. Stimulated salivary secretion occurs when chemoreceptors or pressure receptors in the oral cavity respond to the presence of a substance, such as xylitol gum. These receptors initiate afferent nerve impulses transmitted to the salivary center in the medulla oblongata, which then activates autonomic efferent nerves to stimulate the salivary glands, resulting in increased salivary flow. The mechanical stimulation from chewing plays a significant role in activating pressure receptors and enhancing this process.

CONCLUSION

Oral candidiasis, primarily caused by *Candida albicans*, is a fungal infection that can become pathogenic in patients with predisposing factors such as diabetes mellitus. The immunosuppression linked to diabetes increases vulnerability to opportunistic infections like oral candidiasis, which typically presents as white patches on the oral mucosa and can be associated with burning mouth syndrome (BMS) and xerostomia. These symptoms often coexist and may exacerbate one another, particularly in diabetic patients. Effective treatment requires early diagnosis and a comprehensive approach, combining topical antifungals (e.g., Nystatin Oral Suspension), systemic therapy (e.g., Fluconazole 150 mg), and supportive care such as supplements (e.g., Becomzet), as demonstrated by the successful resolution in the presented case. Future research should explore the mechanistic links between diabetes-induced immune dysfunction, xerostomia, and the pathogenesis of BMS in candidiasis, aiming to develop targeted therapeutic strategies that address both systemic and local factors for improved patient outcomes.

REFERENCES

- Abbas, Mariam Safaa, Abdullah, Ahmed Yousif, Mohammed, Mustafa Kareem, & Al-Mahmood, Sumayah. (2025). *Treatment Of Oral Thrush And Oral Ulcer*.
- Bechman, Katie, Russell, Mark D., Biddle, Kathryn, Gibson, Mark, Adas, Maryam, Yang, Zijing, Patel, Samir, Dregan, Alex, Walsh, Sarah, & Brex, Peter. (2025). Incidence, Prevalence, And Mortality Of Sarcoidosis In England: A Population-Based Study. *The Lancet Regional Health–Europe*, 53.
- Berbudi, Afiat, Khairani, Shafia, & Tjahjadi, Adi Imam. (2025). Interplay Between Insulin Resistance And Immune Dysregulation In Type 2 Diabetes Mellitus: Implications For Therapeutic Interventions. *Immunotargets And Therapy*, 359–382.

Multisymptom Oral Presentation in Type II Diabetes Mellitus: A Case of Candidiasis, Xerostomia, and Burning Mouth Syndrome

- Bertolini, Martinna, Costa, Raphael Cavalcante, Barão, Valentim Adelino Ricardo, Villar, Cristina Cunha, Retamal-Valdes, Belen, Feres, Magda, & Silva Souza, João Gabriel. (2022). Oral Microorganisms And Biofilms: New Insights To Defeat The Main Etiologic Factor Of Oral Diseases. *Microorganisms*, Vol. 10, P. 2413. MDPI.
- Cao, Yanfan, Huang, Shan, Du, Jingyun, Wang, Xiuqing, Gan, Guowu, Chen, Shuai, & Huang, Xiaojing. (2025). Streptococcus Mutans Lias Gene Regulates Its Cross-Kingdom Interactions With Candida Albicans To Promote Oral Candidiasis. *Biorxiv*, 2002–2025.
- Faccioni, P., Montagna, P., Colapinto, G., Zangani, A., Melloni, F., Di Cosola, M., Beccherle, M., Ventorre, D., De Manzoni, R., & Lobbia, G. (2025). Oral Candidiasis: Manifestations, Treatment And Management In Immunocompromised Patients. *Journal Of Applied Cosmetology*, 43(2), 37.
- Grisi, Daniela Corrêa, Vieira, Isabel V, De Almeida Lima, Ana Karolina, De Oliveira Mattos, Mariana Caldas, Damê-Teixeira, Nailê, Salles, Loise Pedrosa, De Oliveira, Laudimar Alves, Stefani, Cristine, & Do Carmo Machado Guimarães, Maria. (2022). The Complex Interrelationship Between Diabetes Mellitus, Oral Diseases And General Health. *Current Diabetes Reviews*, 18(3), 8–22.
- Keser, Gaye, & Pekiner, Filiz Namdar. (2025). Burning Mouth Syndrome (BMS) In Dentistry. *Diagnosis, Treatment And Application In Dentistry Studies 2025–II*, 63.
- Kotsiri, Ioanna, Xanthi, Maria, Domazinaki, Charalampia Melangeli, & Magiorkinis, Emmanouil. (2025). The Role Of Viral Infections In The Immunopathogenesis Of Type 1 Diabetes Mellitus: A Narrative Review. *Biology*, 14(8), 981.
- Martins Almeida, Nara Lígia, Oliveira, Gabriela Moraes, Santos, Carlos Ferreira, Lara, Vanessa Soares, & Cardoso, Camila Lopes. (2025). Challenges Of Diagnosis And Management Of Burning Mouth Syndrome: A Literature Review. *Current Aging Science*, 18(2), 102–119.
- Nanditha, Arun, Chamukuttan, Snehalatha, Raghavan, Arun, & Ramachandran, Ambady. (2020). Global Epidemic Of Type 2 Diabetes Mellitus: An Epidemiologist's Perspective. *Current Trends In Diabetes*, 36, 30.
- Nusynowitz, Jake, Hanson, Mitchell, Gessner, Nicholas, Montoya, Marco, Ramos-Aguilar, César A., Gustafson, David, Plaza, Jose A., & Trinidad, John. (2025). Infectious Diseases Of The Genitals. *A Comprehensive Guide To Genital Skin Disease*, 33–109.
- Park, Younjung. (2025). *Xerostomia And Its Impact On Oral Health*.
- Parsi, Parinaz, Saharkhiz, Saber, Farani, Marzieh Ramezani, Bakhtiyari, Salar, & Alipourfard, Iraj. (2025). Drug-Induced Regeneration Of Pancreatic Betaular Therapeutic Targe Cells: An Approach To Cellts. *Cell Regeneration*, 14(1), 39.
- Ray, Rina Rani. (2023). Periodontitis: An Oral Disease With Severe Consequences. *Applied Biochemistry And Biotechnology*, 195(1), 17–32.
- Rodrigues, Célia F., Rodrigues, Maria Elisa, & Henriques, Mariana. (2019). Candida Sp. Infections In Patients With Diabetes Mellitus. *Journal Of Clinical Medicine*, 8(1), 76.
- Tamai, Riyoko, & Kiyoura, Yusuke. (2025). Candida Infections: The Role Of Saliva In Oral Health—A Narrative Review. *Microorganisms*, 13(4), 717.
- Tkaczyk, Marcin, Kuśka-Kielbratowska, Anna, Fiegler-Rudol, Jakub, Niemczyk, Wojciech, Mertas, Anna, Skaba, Dariusz, & Wiench, Rafał. (2025). The Prevalence And Drug Susceptibility Of Candida Species And An Analysis Of Risk Factors For Oral Candidiasis—A Retrospective Study. *Antibiotics*, 14(9), 876.
- Ye, Mingfeng, Yao, Jizhao, Huang, Huanliang, & Chen, Dexiong. (2025). Association Between Weight-Adjusted Waist Index And Depression In Adults With Diabetes: A Cross-Sectional Study. *BMC Psychiatry*, 25(1), 802.

Multisymptom Oral Presentation in Type II Diabetes Mellitus: A Case of Candidiasis, Xerostomia, and Burning Mouth Syndrome

- Yen, Chih Ching, Tsai, Chung Liang, Chang, Gary Ro Lin, Ko, Chi Hua, Tu, Min Yu, Lan, Ying Wei, Chen, Hsiao Ling, & Chen, Chuan Mu. (2025). Kefir-Derived Exopolysaccharide Ameliorates Hyperglycemic Control And Beta Cell Integrity In A Rat Model Of Type 2 Diabetes Mellitus. *Nutrition & Diabetes*, 15(1), 36.
- Zhao, Hongsen, Ran, Shujun, Huo, Wenqian, Gan, Kang, & Li, Wenlu. (2025). Xerostomia Correlates With Pain Sensitivity In Burning Mouth Syndrome Patients. *Scientific Reports*, 15(1), 13191.